



FACULDADE DE MEDICINA DA UNIVERSIDADE DE COIMBRA

**TRABALHO FINAL DO 6º ANO MÉDICO COM VISTA À ATRIBUIÇÃO DO
GRAU DE MESTRE NO ÂMBITO DO CICLO DE ESTUDOS DE MESTRADO
INTEGRADO EM MEDICINA**

MARIANA TEIXEIRA PINTO FERREIRA PACHECO

***SPASTIC PARAPLEGIA WITH JUVENILE ONSET
OPTIC NEUROPATHY***

ARTIGO CIENTÍFICO - CASE REPORT

ÁREA CIENTÍFICA DE OFTALMOLOGIA

**TRABALHO REALIZADO SOB A ORIENTAÇÃO DE:
PROF. EDUARDO SILVA**

FEVEREIRO/2014

Spastic Paraplegia with juvenile onset optic Neuropathy

Case Report

Abstract

Hereditary Spastic Paraparesis (HSP) represents a group of genetically determined heterogeneous diseases. Mutations in the *SPG7* (Paraplegin) gene, are responsible for a wide range of clinical presentations, varying from an autosomal recessive form of HSP to a form of ADON (Autosomal Dominant Optic Neuropathy), whose clinical characteristics are physiologically based on mitochondrial dysfunction. The impact of optic involvement clinically determined or revealed by supplementary diagnostic means as a clinical biomarker of HSP7 is to be valued.

We present a case report of a 23 year-old, caucasian male with a childhood-onset progressive spastic paraplegia with juvenile-onset rapidly progressive severe optic neuropathy. We aim to highlight the importance of a complete ophthalmological evaluation when a facing a probable neurodegenerative disorder consistent with HSP, in order to correctly characterize the underlying clinical syndrome and efficiently request supplementary diagnostic exams.

Keywords: Hereditary Spastic Paraparesis; SPG7; Optic Neuropathy; Paraplegin; Mitochondria;

Abbreviations

ADON = Autosomal Dominant Optic Neuropathy;
BCVA = Best Corrected Visual Acuity;
CK = Creatine Kinase; EMG = Electromyography;
DOA = Dominant Optic Atrophy;
DTI = Diffusion Tensor Imaging;
FDT = Frequency Doubling Technology perimetry
HSP = Hereditary Spastic Paraparesis;
LHON = Leber's Hereditary Optic Neuropathy;
RNFL = Retinal Nerve Fiber Layer;
SDH = Succinate Dehydrogenase;
SPG7= Spastic Paraplegia Gene 7;
VEP = Visual Evoked Potentials; ERG =Electroretinography;

Introduction

Neurons are important building blocks of the central and peripheral nervous system. Neurons are composed of a cell body, the axons (transmit information) and the dendrites (receive and process information). The axons represent up to 99% of the total cellular volume, and that characteristic emerges as the main cause of their energy dependence to obtain proteins and lipids and to eliminate residues.(Rugarli and Langer 2006)

Genetically affected axons degenerate from the processes towards the cell body, in a so called “dying-back” manner, of which HSP is an example.(Rugarli and Langer 2006)

The pathophysiological process through which axons of cortical motor neurons degenerate, ultimately explains the progressive spasticity and weakness in the lower limbs, which appear as major characteristics of hereditary spastic paraplegia, an heterogeneous genetically determined group of diseases. (Klebe et al. 2012) The estimated prevalence is of 3-10 per 100,000 in Europe.(Yu-Wai-Man, Griffiths, and Chinnery 2011)

The type of inheritance of HSP may be autosomal dominant or recessive and X-linked-recessive. In 80% of the cases, a form of dominant inheritance is present.

The onset of the HSP often takes place between the age of 10 and 45 years old, according to the causative genetic defect, and the observed phenotype expressed may be classified as pure or complex taking into account the clinical characteristics of the disease.(Klebe et al. 2012; Yu-Wai-Man et al. 2011)

The pure phenotype is defined by the presence of progressive paraparesis and possible posterior column or bladder involvement, in the absence of other additional features.(Arnoldi et al. 2008; Klebe et al. 2012; Wilkinson et al. 2004)

The complex phenotype expresses, in addition to the basic symptoms that define the pure phenotype, other neurological signs or clinical features such as cognitive impairment, polyneuropathy, generalized epilepsy, hearing impairment, atrophy of corpus callosum,

extrapyramidal symptoms and/or tetraspasticity. (Arnoldi et al. 2008; Klebe et al. 2012; Wilkinson et al. 2004)

Mitochondrial Diseases which present with Optic Neuropathy – Pathophysiology

The HSP causative genes can, according to their hypothetical function, be divided into three groups. The axonal trafficking genes (*SPG3*, *SPG4* and *SPG10*), the myelination and neuronal recognition genes (*SPG1* and *SPG2*) and the genes with mitochondrial functions.(Rugarli and Langer 2006)

Three examples of mitochondrial forms of HSP are associated with mutations in the *SPG31* gene (*REEP1*), the *SPG13* gene (heat shock protein) and in the *SPG7* gene (Paraplegin).

The impact of the underlying mutations in the optimal mitochondrial performance, which ultimately affects several energy-dependent circuits and exposes cells to oxidative stress, results in the clinically identifiable syndromes (Atorino L, *et al.*, 2003).

There is a tendency for Mitochondrial Diseases to impact retinal function, potentially leading to optic neuropathy. This fact can be explained by the high energy-dependence of the retinal ganglion cells (RGC). The RGC represent the final output of the retina and their axons project inwards to form the optic nerve that subsequently conducts the impulse to the lateral geniculate body and subsequently to the occipital lobes of the brain. Posterior to the lamina cribosa, the optic nerve is myelinated but in the intraocular portion, the axons remain unmyelinated and, therefore, more energy-dependent, in order to transmit the potential of action. This is corroborated by the number of mitochondria which is a lot higher in the unmyelinated portion, underlining the greater vulnerability to mitochondria dysfunction and energy decreased production of that part of the optic pathway.(Carelli et al. 2009)

Mitochondrial disorders that present with optic neuropathy can be classified as syndromic or non-syndromic.(Carelli et al. 2009) In the group of syndromic mitochondrial diseases with optic neuropathy, a type of multi-systemic mitochondrial disorder is

LHON/dystonia/MELAS/Leigh overlapping syndrome, which results from a defect in mtDNA, leading to mitochondrial vasculopathy and affecting the complex I of the mitochondria. Genetic errors in nuclear genes that code for mitochondrial proteins, as those underlying conditions such as Friedreich Ataxia, Charcot-Marie-Tooth type 2A2, Mohr-Tranebjerg syndrome (deafness-dystonia-optic atrophy), DOA “plus” syndrome, DOA with cataract, Costeff Syndrome and HSP 7, represent different genetic sources for several syndromic mitochondrial diseases with optic neuropathy.(Carelli et al. 2009) The non-syndromic or mono-symptomatic group of mitochondrial diseases causing optic neuropathy includes Leber Hereditary Optic Neuropathy (LHON), Dominant Optic Atrophy (DOA: OPA1; OPA7; OPA4; OPA5 genes) and also ADON associated with *SPG7* gene.(Carelli et al. 2009)

Hereditary Spastic Paraplegia Type 7

Hereditary Spastic Paraplegia type 7 is a form of HSP that results from a mutation in the *SPG7*, encoding Paraplegin that constitutes a subunit of the ubiquitous and ATP-dependent mAAA protease, which integrates the inner mitochondrial membrane. (Klebe et al. 2012; Mancuso et al. 2012; Rugarli and Langer 2006)

SPG7 was the first gene identified as causative of autosomal spastic paraplegia (16q24.3) and is composed of 17 exons, with high frequency of rare nucleotide variants of unknown status, which makes the interpretation of molecular testing results a complex task. Mutations in the *SPG7* gene were first identified in 3 families, two with isolated spasticity and one with complex phenotype.

Clinical characteristics and typical evolution of *SPG7*-related phenotypes remain uncertain. Studies have shown that age of onset is higher when compared to the general interval of the HSP group (10-45years old), ranging from 18 to 52 years old (median of 39 y.o.) and patients tend to present a more slowly progressive disease.

The HSP7 presents a recessive pattern of inheritance, as a result of a homozygous or compound heterozygous genotype. (Klebe et al. 2012)

The underlying clinical manifestations vary from a pure to a complex phenotype, and the features associated with the complex form of disease, in descending order of frequency, are: cerebellar involvement and/or mild cerebellar atrophy, optic neuropathy, ptosis and supranuclear palsy.(Klebe et al. 2012)

Patients might clinically present a pure phenotype but if cerebellar signs/ atrophy are identifiable in MRI imaging or if optic neuropathy is diagnosed by OCT (optical coherence tomography), a complex subclinical phenotype is present.(Klebe et al. 2012)

The cerebellar phenotype may be influenced by other genes rather than being a pure consequence of Paraplegin defects. Paraplegin associates with *AFG3L2* (ATPase family gene 3-like 2) to form an Oligomeric mAAA protease complex, that integrates the inner membrane of the mitochondria and is functionally active in the Complex I of the respiratory chain. Mutations in the *AFG3L2* gene are involved in autosomal dominant Spinocerebellar Ataxia Type 28, which can present with a homozygous or heterozygous genotype. In the homozygous form, the disease mainly presents with pyramidal signs, ptosis and/or ophthalmoplegia whereas in the heterozygous state, oculomotor apraxia, dystonia and/or progressive myoclonic epilepsy can be found. (Klebe et al. 2012)

Variants of the *AFG3L2* gene might also act as genetic modifiers of the cerebellar profile of patients who test positive for *SPG7* mutations. Mutations have been reported in exons 10, 15 and 16 but consistent results are yet to be established.

The mAAA (ATPases Associated with diverse cellular Activities) proteases, namely Paraplegin (composed by an association of metallo-peptidase 41 and an ATPase domain), have been reported to interfere with the processing of OPA 1 (a conserved dynamin-like

GTPase in the inner membrane that regulates the dynamic functioning of the mitochondria) through its proteolytic cleavage.(Arnoldi et al. 2008)

The *OPA1* gene is involved in the pathogenesis of the ADOA (Autosomal Dominant Optic Atrophy), which represents an important type of non-syndromic mitochondrial disease causing optic neuropathy. After its cleavage by mitochondrial proteases, OPA1 is imported into the intermembrane space generating long (L) and short (S) forms of the protein. These two forms separately are virtually non-functional, but when bound they trigger mitochondrial network fusion. The lack of correct proteolytic cleavage eventually results in mitochondrial dysfunction, apoptosis and loss of retinal ganglion cells (RGC).(Arnoldi et al. 2008)

The protein activation and degradation in mitochondria, by m-AAA proteases are two interdependent and mutually influenced processes.

A role of Paraplegin in the quality control of mitochondria, including maturation of proteins involved in ribosome assembly and translation within the mitochondria such as MrpL32 (a nuclear-encoded subunit of mitochondrial ribosomes), as well as protein synthesis, has been suggested. This can widen the impact of the mutation in *SPG7* in the pathogenesis of the ADON secondary to *SPG7* and HSP7.(Rugarli and Langer 2006)

Mutations in the *SPG7* gene have been studied in yeast and mice, and interesting findings have shed some understanding about the subject. Axonal swelling was present in mice and probably originated from axonal deficient transport, with subsequent accumulation of neurofilaments. These facts link *SPG7* HSP to other forms of disease. (Ferreirinha 2004). Enlarged abnormal mitochondria were also found in the synaptic terminal of the motor neurons' axons of Paraplegin-deficient mice, fact that was not yet explained. These mitochondrial changes were specific of long axons (Ferreirinha 2004). Some putative theories have been proposed to explain the abnormal findings in neurons as well as the caudal-cranial onset of neurodegenerative symptoms.

It has been shown that mitochondria with higher membrane potential are preferably located in synapses, whereas old mitochondria tend to be transported towards the cell body in order to be replaced. Kinesins and dyneins (motor proteins that move along the microtubules inside the cell) have been involved in this selective transport of mitochondria and have also been implicated in neurodegeneration. (Miller, K.E. and Sheetz 2004; Reid 2002) Thus, the energy deficiency in *SPG7* mutants can enlighten the fact that the symptoms derive from affected long axons in their distal portion, because mitochondria that are more apart from the cell body are more poorly replaced. Another hypothesis is based on clogging of axons by enlarged mitochondria that consequently impairs the axonal transport and leads to neuronal degeneration. (Chen, H., and Chan 2005; Ferreirinha 2004)

Autosomal Dominant Optic Neuropathy *SPG7*

The isolated affection of the optic nerve caused by mutation in the *SPG7* gene is an uncommon form of Autosomal Dominant Optic Neuropathy (ADON). A heterozygous missense, the Asp411Ala mutation, has specifically been linked to this form of ADON. The *SPG7* gene maps to chromosome 16q24.3, has two alanines downstream of the Walker B motif and is up to date, the only naturally occurring missense mutation in the AAA domain of the protein. The Walker B motif associates with the Walker A motif to promote the fixation and hydrolysis of ATP. Therefore the Asp411Ala mutation alters the binding/hydrolysis of ATP, leading to a decrease in proteolytic activity of mAAA proteases in RGC, and to their subsequent apoptosis.

Diagnostic Criteria

The diagnosis of SPG7 – HSP is based in the following clinical and contextual features: slowly progressive bilateral inferior limbs' weakness, decreased vibratory sense, spasticity, neurological examination showing the presence of a pure (extensor plantar responses, hyperreflexia and decrease in lower limbs vibratory sense) or a complex phenotype (optic disc pallor, ptosis, dysphagia, cognitive impairment, motor upper limb symptoms, bladder involvement, ataxia, nystagmus, strabismus, hearing impairment, scoliosis, pes cavus, motor and sensory neuropathy and muscular atrophy) and the presence of a family history supporting an autosomal recessive inheritance.

Facing a set of symptoms consistent with HSP7, a supplementary evaluation should be proposed and there are some expectable findings if the diagnosis is in fact correct. Brain MRI may disclose cerebellar/cortical atrophy (Salinas S et al. 2008; Warnecke T et al 2007; Wilkinson et al. 2004) and DTI (Diffusion Tensor Imaging – an MRI technique that measures the diffusion of water in tissues) white matter abnormalities can be expected, especially if located to the frontal lobe, the corticospinal tracks or the brain stem.(Warnecke T et al 2010) Functional neurological studies, including spinal evoked potentials or transcranial magnetic stimulation, may demonstrate delayed prolongation of central motor conduction time and motor threshold in the lower limbs of affected individuals.(Casari G. Marconi R., 2006; Warnecke T et al, 2007)

Muscle biopsies are often performed in patients suspected to carry *SPG7* mutations. The absence of abnormalities in the muscles biopsy cannot exclude the presence of *SPG7* mutations, as it can simply reflect the early stage of the disease. These biopsies may show signs of denervation with partial reinnervation, marked excess of type I fibers probably due to the chronic spasticity, atrophic type II fibers and ragged-red fibers (when stained with the modified Gomori trichrome) with intense staining with the histochemical reaction to SDH,

reflecting the mitochondrial proliferation in an attempt to compensate the OXPHOS defect, and negative to cytochrome C oxidase, complex IV of the respiratory chain, which is a common denominator among mitochondrial diseases.(Casari et al. 1998) Serum CK may be raised and EMG may reveal axonal motor sensory neuropathy.

Genetic testing provides a definitive diagnosis, as it allows the identification of a disease-causing mutation. Sequence analysis may be applied as a first approach. If only one or no mutation is found, a deletion/duplication analysis should follow.

Patient and Methods

We present a case report of a 23 years old caucasian male, exhibiting clinical features consistent with hereditary spastic paraplegia, peripheral neuropathy and bilateral rapidly progressive optic neuropathy. Detailed phenotypic characterization was performed, including family history, best-corrected visual acuity (BCVA), slit-lamp examination, fundus examination, fundus photography, FDT perimetry, and electrophysiological studies, in accordance with ISCEV guidelines.

Colour fundus photographs (35°) of both eyes (centered to the macula and to the optic nerve) were taken in order to document the features of these structures, with a Topcon TRC-50 IA Retinal Ophthalmic Camera.

Achromatic contrast sensitivity within the magnocellular pathway was probed using a perimetric test based on frequency doubling technology Vertically oriented sinusoidal grating stimuli were presented monocularly, with a spatial frequency of 0.25 cpd modulated at 25 Hz, at different contrast levels, by means of Humphrey Matrix Visual Field Instrument (Carl Zeiss Meditec Inc., USA). Analysis was performed considering both global parameters (MD – mean defect and PSD – pattern standard deviation) and contrast sensitivity pooled from five

regions: the 5° central area (C) and the four visual field quadrants (ST- superior temporal, SN- superior nasal, IN- inferior nasal and IT- inferior temporal).

Conventional Visual Evoked Potentials (Pattern VEPs) were used to measure the functional integrity of retino-cortical visual pathways. A RETIport32 (Roland Consult, Germany) device was used for stimulation and electrophysiological recordings, with a pattern reversal checkerboard stimulus, at a contrast level of 97 %, on a 20 inch monitor at a viewing distance of one metre. Two spatial frequencies (60' and 15') were monocularly presented at 1.5 reversals/sec, at a frame rate of 60 Hz.

Genomic DNA was prepared from venous leukocytes and for genetic testing, coding exons and flanking intronic regions of *SPG7* and the *SPG31* genes were PCR-amplified, purified, and sequenced. The *SPG7/SPG31* genes were automatically sequenced using previously described primer sets.(Elleuch et al. 2006) This was part of an international collaboration with Hopital Necker des Enfants Malades, Paris.

This study was approved by the local ethics committee and followed the tenets of the Declaration of Helsinki. Informed consent was obtained from the patient prior to collection of clinical data and genomic samples.

He is integrated in APCC, an association that supports families and patients with cerebral palsy, which was the first suspected diagnostic (diplegic form), as the patient also presents some degree of cognitive impairment in addition to the early onset of motor dysfunction of the lower limbs. Left kidney agenesis was detected in post-natal period. Consanguinity was excluded and there was no family history of spastic paraplegia.

In 2003, at age 13, the patient underwent his first ophthalmological observation, which was within normal limits.

In 2006, a bilateral loss of visual acuity was determined (BCVA OD 6/10 and OS 6/10) along with a reduction in pupillary reflexes, no relative afferent papillary defect and optic disc pallor OU. The remainder exam was normal.

Electrophysiological studies were conducted, including pattern and flash VEP and ERG. Pattern Visually Evoked Potentials (VEP) appeared bilaterally abolished (Figure 1). Flash VEP presented reduced responses at 1,3Hz and 7Hz. (Figure 2)

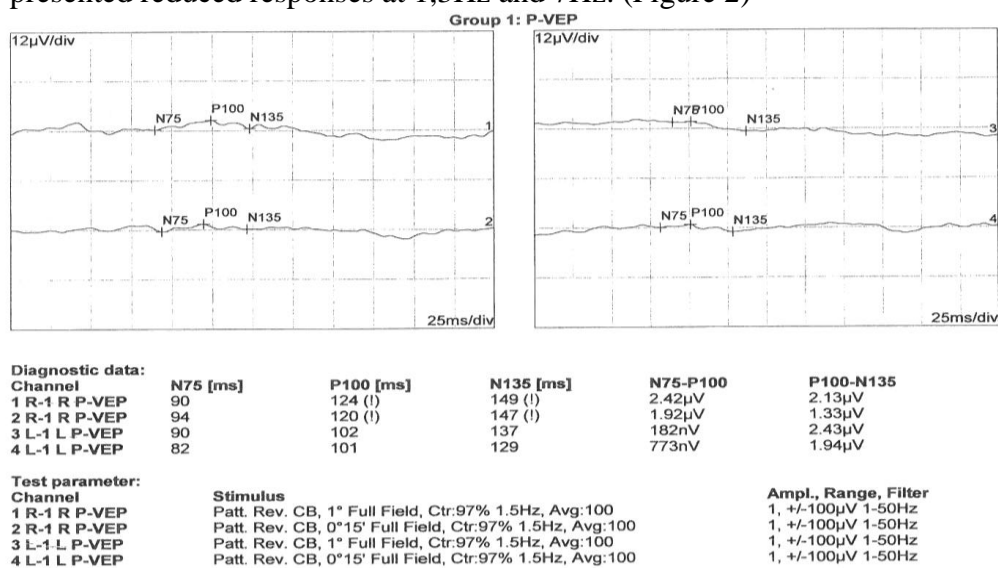


Figure 1 – Bilaterally abolished pattern VEPs

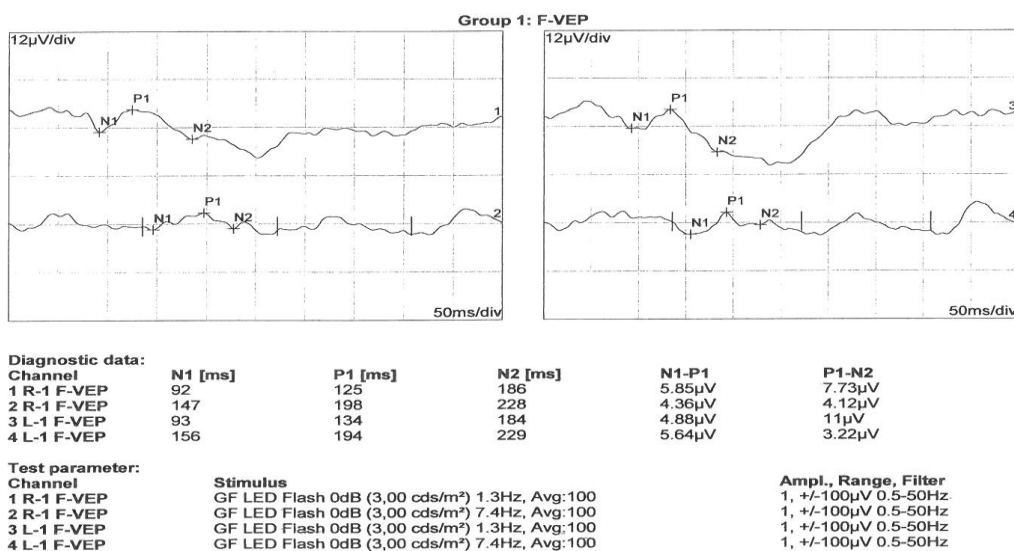


Figure2- Flash VEP displaying very reduced responses at 1,3Hz and 7Hz.

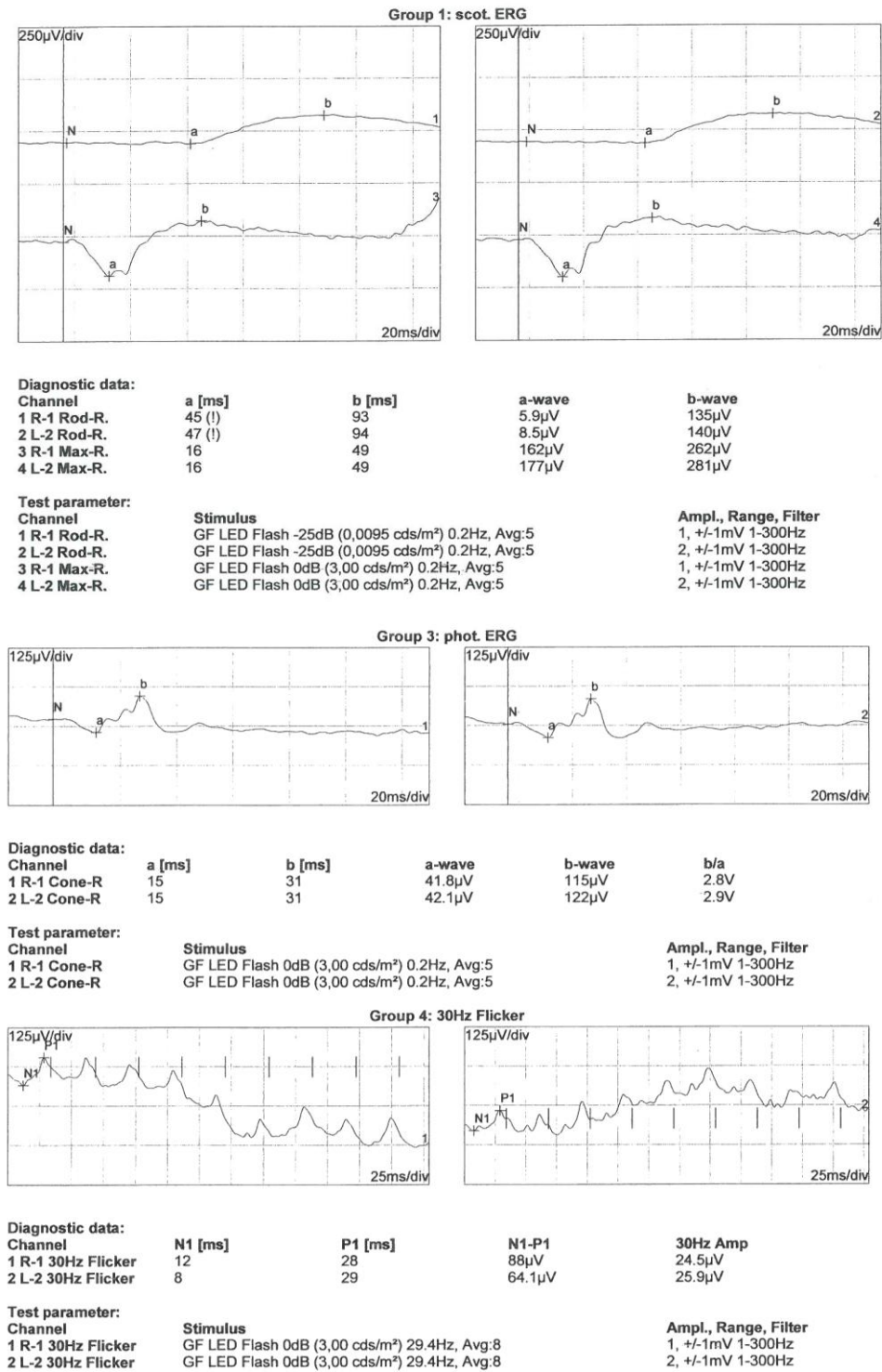


Figure 3 – ERG confirming preserved responses in scotopic and photopic conditions.

ERG revealed normal scotopic and photopic responses that point towards the integrity of the neurosensory retina. Flicker response and oscillatory potentials were also within expected intervals (Figure 3) Taken together, the electrophysiological study results are suggestive of a optic neuropathy.

FDT perimetry demonstrated arcuate scotomas and reduced sensitivity temporal to the disc compatible with bilateral temporal optic atrophy with significant drop out of the retinal nerve fiber layer (RNFL), with loss of central vision more severe in the left eye (Figure 4).

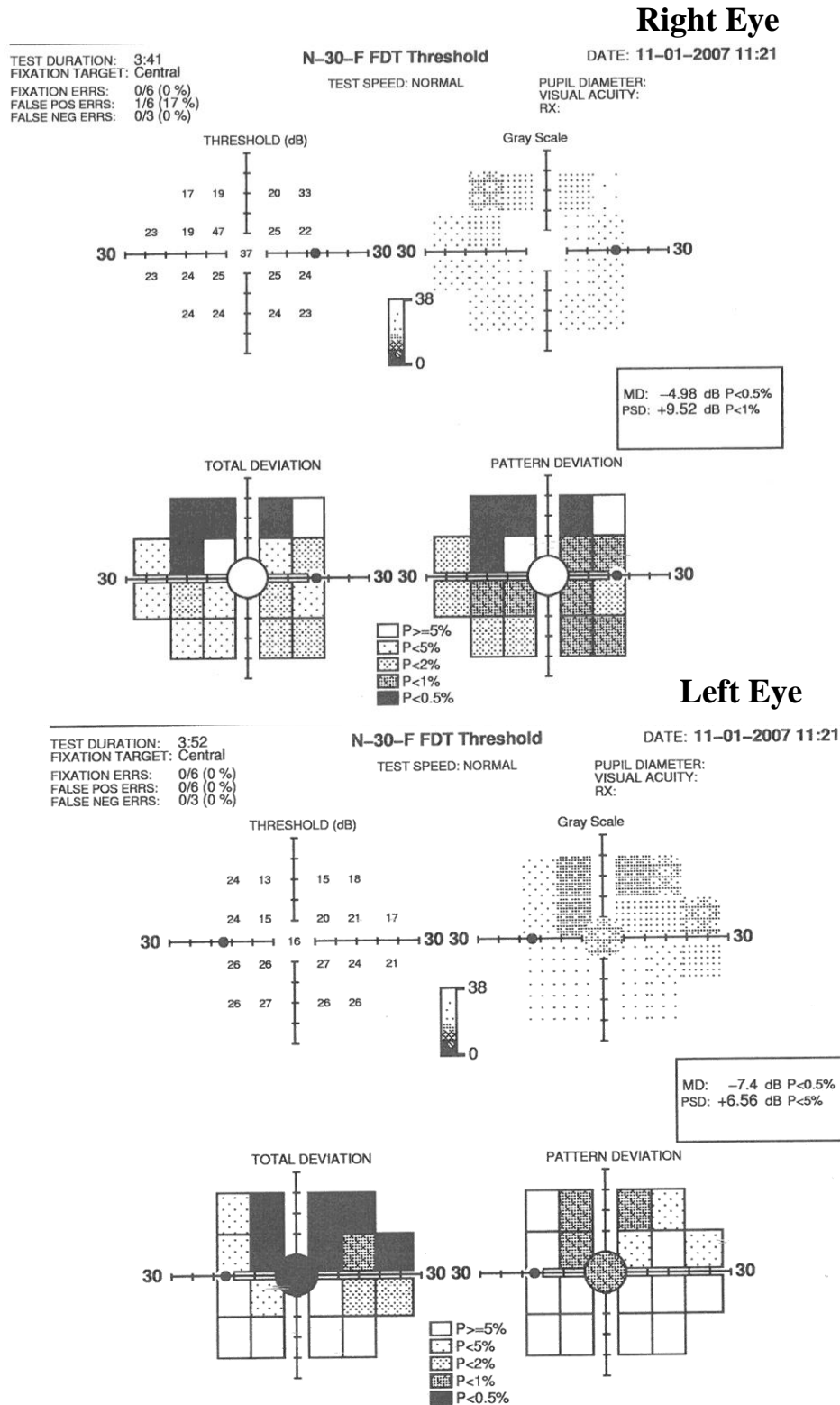


Figure 4 – N-30-F FDT Threshold results obtained using standard technique.

In 2008, BCVA was of 5/10 OD and 2/10 OS. The patient showed no evidence of ptosis, ophthalmoplegia and/or strabismus.

In 2010, at age 20, patient already presented a drop in BCVA to 2/10 OU and at his last observation, in October 2013, BCVA was inferior to 1/10 bilaterally, with further drop-out of the RNFL.

Molecular testing of the *SPG31* and *SPG7* genes are underway. Automated sequencing of the *SPG7* gene was normal in all but three exons. Molecular results are pending.

Discussion

In contrast with the finding in virtually all studies that age of onset for SPG7-HSP was higher (median 39years) and disease course was longer and slowly progressive, our patient presents with a juvenile onset, rapidly progressive hereditary spastic paraplegia. (Klebe et al., 2012; McDermott CJ et al., 2001).

The main characteristic supporting the hypothesis of a SPG7-HSP in our patient is the major optic involvement when associated with symptoms of spasticity and motor impairment of lower limbs.

When analyzing the ophthalmological data, it should be underscored the significant vision loss throughout a 10-year period. In 2003 the ophthalmological exam was normal and in 2013, the BCVA was below 1/10 in both eyes, which dramatically demonstrates the severity of the loss of retinal ganglion cells in this patient.

Electrophysiological results are highly suggestive of optic neuropathy, with preservation of the neurosensory retina as corroborated by the ERG results that showed

scotopic (rods), photopic (cones), flicker (cones) and oscillatory potentials (ischemia) normal responses. In addition, pattern and flash VEP (evaluates function of visual pathways and striate cortex) showed optic nerve dysfunction, with abolished responses in the tests.

The temporal half of neuroretinal rim is whiter and reflects the loss of axons of RGC, which are replaced by glial tissue. The optic disc pallor is a valuable clinical finding of optic neuropathy along with diminished pupillary reflexes that also mirrors visual pathway integrity. Both features were present in our patient.

The optic neuropathy was found in all patients who tested positive for *SPG7* mutations in a previous large study. (Klebe et al. 2012) This highlights the outstanding importance of an ophthalmological observation, when a probable diagnosis of a neurodegenerative disorder with lower limb motor impairment and spasticity is suggested. The ophthalmological evaluation may precede the genetic analysis in order to provide better guidance to the patient, because if an optic neuropathy is diagnosed, the presence of a *SPG7* mutation becomes a more appealing possibility as the probable cause of the underlying pathology, and genetic confirmation is required. After the description of a *SPG7* mutation, it is also mandatory to follow-up the patient from an ophthalmological standpoint determine the disease impact and to infer which treatment should be implemented.

Our patient is taking a daily dose of coenzyme Q10 therapy (ubiquinone – helps transfer electrons in the respiratory chain acts as an antioxidant and helps protect cells against oxidative damage) since a probable mitochondrial disorder was considered.(Abe K, Matsuo Y, Kadekawa J, Inoue S 1999) The benefit of this compound is unclear but there are reports of potential positive effects in some patients, ameliorating clinical symptoms, upgrading enzyme function and slowing the course of disease, and as unpleasant side effects are rare, it is promptly introduced in these situations.

In addition, topical brimonidine (alfa2-receptors selective agonist, with minimal systemic adrenergic effects), may be used as a potencial neuroprotector as it lowers intraocular pressure.(Hernández, Urcola, and Vecino 2008)

Initial efforts have been attempted in animal models in order to develop a gene-replacement therapy, using an adeno-associated viral vector encoding *Spg7* cDNA.

There were several indicators of a positive effect of this therapeutic approach in mice with *Spg7* gene inactivation, such as reduction in the number of swollen axons and in the percentage of axons containing abnormal mitochondria, and subsequent improvement of motor ability. However, mitochondrial morphology defects started to appear some time later, which suggests a transient effect of this therapeutic option .(Pirozzi et al. 2006) Gene therapy, isolated or in combination with cell replacement therapies, may represent a true hope in the control of such devastating condition.

Acknowledgements

This work was carried out during the years of 2013-2014 at the Faculty of Medicine, University of Coimbra, Portugal. I wish to sincerely acknowledge my supervisor, Professor in Pediatric Ophthalmology, Eduardo Silva MD, Ph.D. His continuous optimism concerning this work, encouragement and measureless academic support allowed this paper to be successfully completed.

I warmly thank my family, my boyfriend and my friends, who have always believed in me more than I have myself, for their patience and their invaluable presence.

I also wish to present my deepest gratitude to Dr. Maria do Resgate Salta, who has taught me the importance of doctor-patient relationship, during this academic year.

Finally, I wish to present a special word of admiration to my Pediatrician, Dr. Renato Barbosa who has led me to fully understand what it should mean to be a doctor.

References

- Abe K, Matsuo Y, Kadekawa J, Inoue S, Yanagihara T. 1999. "Effect of Coenzyme Q10 in Patients with Mitochondrial Myopathy, Encephalopathy, Lactic Acidosis, and Stroke-like Episodes (MELAS): Evaluation by Noninvasive Tissue Oximetry." *J Neurol Sci* 162:65–68.
- Arnoldi, Alessia et al. 2008. "A Clinical, Genetic, and Biochemical Characterization of SPG7 Mutations in a Large Cohort of Patients with Hereditary Spastic Paraplegia." *Human mutation* 29(4):522–31. Retrieved February 6, 2014 (<http://www.ncbi.nlm.nih.gov/pubmed/18200586>).
- Atorino L, Silvestri L, Koppen M, Cassina L, Ballabio A, Marconi R, et al. 2003. "Loss of M-AAA Protease in Mitochondria Causes Complex I Deficiency and Increased Sensitivity to Oxidative Stress in Hereditary Spastic Paraplegia." *J Cell Biol* 163:777–87.
- Carelli, Valerio et al. 2009. "Retinal Ganglion Cell Neurodegeneration in Mitochondrial Inherited Disorders." *Biochimica et biophysica acta* 1787(5):518–28. Retrieved February 8, 2014 (<http://www.ncbi.nlm.nih.gov/pubmed/19268652>).
- Casari, G. et al. 1998. "Spastic Paraplegia and OXPHOS Impairment Caused by Mutations in Paraplegin, a Nuclear-Encoded Mitochondrial Metalloprotease." *Cell* 93(6):973–83. Retrieved (<http://www.ncbi.nlm.nih.gov/pubmed/9635427>).
- Casari G. Marconi R. 2006. "Spastic Paraplegia 7." *NCBI Bookshelf*.
- Chen, H., and Chan, D. C. 2005. "Emerging Function of Mammalian Mitochondrial Fusion and Fission." *Hum Mol Genet* 14 Spec No:R283–289.
- Elleuch, N. et al. 2006. "Mutation Analysis of the Paraplegin Gene (SPG7) in Patients with Hereditary Spastic Paraplegia." *Neurology* 66:654–59.
- Ferreirinha, F. et al. 2004. "Axonal Degeneration in Paraplegin-Deficient Mice Is Associated with Abnormal Mitochondria and Impairment of Axonal Transport." *J. Clin. Invest.*
- Van Gassen, Koen L. I. et al. 2012. "Genotype-Phenotype Correlations in Spastic Paraplegia Type 7: A Study in a Large Dutch Cohort." *Brain : a journal of neurology* 135(Pt 10):2994–3004. Retrieved February 6, 2014 (<http://www.ncbi.nlm.nih.gov/pubmed/22964162>).
- Hernández, María, J. Haritz Urcola, and Elena Vecino. 2008. "Retinal Ganglion Cell Neuroprotection in a Rat Model of Glaucoma Following Brimonidine, Latanoprost or Combined Treatments." *Experimental eye research* 86(5):798–806. Retrieved February 13, 2014 (<http://www.ncbi.nlm.nih.gov/pubmed/18394603>).

- Klebe, Stephan et al. 2012. "Spastic Paraplegia Gene 7 in Patients with Spasticity And/or Optic Neuropathy." *Brain : a journal of neurology* 135(Pt 10):2980–93. Retrieved February 6, 2014 (<http://www.pubmedcentral.nih.gov/articlerender.fcgi?artid=3470714&tool=pmcentrez&rendertype=abstract>).
- Mancuso, Giuseppe, Esther Barth, Pietro Crivello, and Elena I. Rugarli. 2012. "Alternative Splicing of Spg7, a Gene Involved in Hereditary Spastic Paraplegia, Encodes a Variant of Paraplegin Targeted to the Endoplasmic Reticulum." *PLoS ONE* 7(5):e36337. Retrieved February 6, 2014 (<http://www.pubmedcentral.nih.gov/articlerender.fcgi?artid=3341365&tool=pmcentrez&rendertype=abstract>).
- McDermott CJ, Dayaratne RK, Tomkins J, Lusher ME, Lindsey JC, Johnson MA, et al. 2001. "Paraplegin Gene Analysis in Hereditary Spastic Paraplegia (HSP) Pedigrees in Northeast England." *Neurology* 56:467–71.
- Miller, K.E. and Sheetz, M. P. 2004. "Axonal Mitochondrial Transport and Potential Are Correlated." *J. Cell Sci.* 117, 2791-2804.
- Pirozzi, Marinella et al. 2006. "Intramuscular Viral Delivery of Paraplegin Rescues Peripheral Axonopathy in a Model of Hereditary Spastic Paraplegia." *The Journal of clinical investigation* 116:202–8.
- Reid, E. et al. 2002. "A Kinesin Heavy Chain (KIF5A) Mutation in Hereditary Spastic Paraplegia (SPG10)." *Am. J. Hum. Genet.* 71:1189–94.
- Rugarli, Elena I., and Thomas Langer. 2006. "Translating M-AAA Protease Function in Mitochondria to Hereditary Spastic Paraplegia." *Trends in molecular medicine* 12(6):262–69. Retrieved February 3, 2014 (<http://www.ncbi.nlm.nih.gov/pubmed/16647881>).
- Salinas S et al. 2008. "Hereditary Spastic Paraplegia: Clinical Features and Pathogenic Mechanisms." *Lancet Neurol.* 7:1127–38.
- Warnecke T et al. 2007. "A Novel Form of Hereditary Spastic Paraplegia Caused by a New SPG7 Mutation." *Neurology* 69:368–75.
- Warnecke T et al. 2010. "A Novel Splice Site Mutation in the SPG7 Gene Causing Widespread Fiber Damage in Homoygous and Heteroygous Subjects." *Mov Disord.* 25:413–20.
- Wilkinson, P. A. et al. 2004. "A Clinical, Genetic and Biochemical Study of SPG7 Mutations in Hereditary Spastic Paraplegia." *Brain* 127:973–80.
- Yu-Wai-Man, Patrick, Philip G. Griffiths, and Patrick F. Chinnery. 2011. "Mitochondrial Optic Neuropathies - Disease Mechanisms and Therapeutic Strategies." *Progress in retinal and eye research* 30(2):81–114. Retrieved February 6, 2014 (<http://www.pubmedcentral.nih.gov/articlerender.fcgi?artid=3081075&tool=pmcentrez&rendertype=abstract>).